

Functional organization of perisylvian activation during presentation of sentences in preverbal infants

Ghislaine Dehaene-Lambertz^{*†‡§}, Lucie Hertz-Pannier^{*†||**}, Jessica Dubois^{||}, Sébastien Mériaux^{||}, Alexis Roche^{||}, Mariano Sigman^{*‡}, and Stanislas Dehaene^{*†††}

^{*}Institut National de la Santé et de la Recherche Médicale, U562, and ^{||}Commissariat à l'Énergie Atomique, 4 Place du Général Leclerc, 91400 Orsay, France; [†]Neurologie Pédiatrique, Centre Hospitalier Universitaire Kremlin Bicêtre, and ^{||}Radiologie Pédiatrique, Centre Hospitalier Universitaire Necker-Enfants Malades, Assistance Publique-Hopitaux de Paris, 75015 Paris, France; ^{**}Institut National de la Santé et de la Recherche Médicale, U663, Université Paris 5, 75015 Paris, France; ^{††}Collège de France, 75005 Paris, France; and [‡]Institut Fédératif de Recherche 49, 91400 Orsay, France

Communicated by Michael I. Posner, University of Oregon, Eugene, OR, July 27, 2006 (received for review June 10, 2006)

We examined the functional organization of cerebral activity in 3-month-old infants when they were listening to their mother language. Short sentences were presented in a slow event-related functional MRI paradigm. We then parsed the infant's network of perisylvian responsive regions into functionally distinct regions based on their speed of activation and sensitivity to sentence repetition. An adult-like structure of functional MRI response delays was observed along the superior temporal regions, suggesting a hierarchical processing scheme. The fastest responses were recorded in the vicinity of Heschl's gyrus, whereas responses became increasingly slower toward the posterior part of the superior temporal gyrus and toward the temporal poles and inferior frontal regions (Broca's area). Activation in the latter region increased when the sentence was repeated after a 14-s delay, suggesting the early involvement of Broca's area in verbal memory. The fact that Broca's area is active in infants before the babbling stage implies that activity in this region is not the consequence of sophisticated motor learning but, on the contrary, that this region may drive, through interactions with the perceptual system, the learning of the complex motor sequences required for future speech production. Our results point to a complex, hierarchical organization of the human brain in the first months of life, which may play a crucial role in language acquisition in our species.

functional MRI | language | brain | memory | child

To what extent is the human species predisposed to acquire language? This question is generally debated by comparing the complexity of the speech input with infants' limited processing resources. Infants face the complex problem of being confronted with a continuous auditory signal that they should learn to segment into phonemes, syllables, words, and constituents and combine to understand and produce new information. Because language acquisition is fast, proceeds through a series of reproducible stages, and exhibits a systematicity that seems to go beyond what could possibly be learned from surrounding speech inputs, some researchers have postulated a special-purpose language acquisition device (1). However, infants' capacity of statistical learning (2) combined with the observation that speech possess numerous regularities have strengthened a constructivist view according to which the infant brain progressively extracts regularities in its environmental inputs (3).

In most adults, speech processing relies on a hierarchy of well defined areas centered around the left sylvian fissure. Why does language processing systematically call on those regions? Do they possess special properties that can explain language emergence in humans? Examination of their initial functional organization in the first year of life may ultimately clarify how infants take advantage of their environment to achieve the linguistic sophistication of adults. Thanks to the development of noninvasive brain imaging, we can begin to decipher the cerebral resources at infants' disposal to process speech. In a previous

study (4), in which we monitored functional MRI (fMRI) responses to 20-s blocks of speech, we showed that the brain areas involved in speech listening at 3 months of age are anatomically similar to those described in adults. We observed bilateral activations in the superior temporal sulci, with a significant functional asymmetry toward the left hemisphere at the level of the *planum temporale*. We also observed activation of the angular gyrus and frontal regions activated with forward but not backward speech. Partially similar results were obtained with the coarser resolution of near-infrared spectroscopy (5).

Those earlier results, however, did not clearly establish whether those cortical regions are already functionally differentiated in the infant brain. In the present study, we attempted to analyze the functional organization of perisylvian regions in infants by using two basic functional criteria: speed of response to speech inputs and sensitivity to sentence repetition.

In a recent fMRI study in adults (6), we demonstrated the possibility of parsing brain activations based on the phase of their blood oxygenation level-dependent (BOLD) response to a single sentence. The phase, which estimates the delay in activation relative to sentence onset, varies systematically across perisylvian areas. Increasingly slower responses toward the temporal poles and inferior frontal areas suggest that successive regions integrate speech information on different time scales, perhaps because they are sensitive to speech units of different granularity. To extend this finding to infants, we used the same slow-event-related paradigm with a 2-s-long sentence presented every 14.4 s. Unlike our previous block study, this design allowed us to monitor the speed of the rise and fall of the infant's BOLD response in different brain regions.

Our second goal was to investigate the presence of any memory of speech sounds in the infant brain. To this aim, each stimulus sentence was presented twice at a 14.4-s interval. This design allowed us to study whether some of the infant's language areas, at this early age, are already capable of encoding a short sentence and recognizing its repetition after a brief interval.

Results

Spatiotemporal Characterization of the BOLD Response. Our first analysis took advantage of the periodical stimulus presentation (one sentence every 14.4 s) to estimate the phase of the event-related BOLD response across the whole brain. We mea-

Author contributions: G.D.-L., L.H.-P., J.D., and S.D. designed research; G.D.-L., L.H.-P., and J.D. performed research; M.S. and S.D. contributed new reagents/analytic tools; G.D.-L., J.D., S.M., A.R., and S.D. analyzed data; and G.D.-L., L.H.-P., and S.D. wrote the paper.

The authors declare no conflict of interest.

Abbreviations: fMRI, functional MRI; BOLD, blood oxygenation level-dependent; EPI, echo planar image.

Data deposition: The neuroimaging data have been deposited with the fMRI Data Center, www.fmridc.org (accession no. 2-2006-1228W).

[§]To whom correspondence should be addressed. E-mail: ghislaine.dehaene@cea.fr.

© 2006 by The National Academy of Sciences of the USA

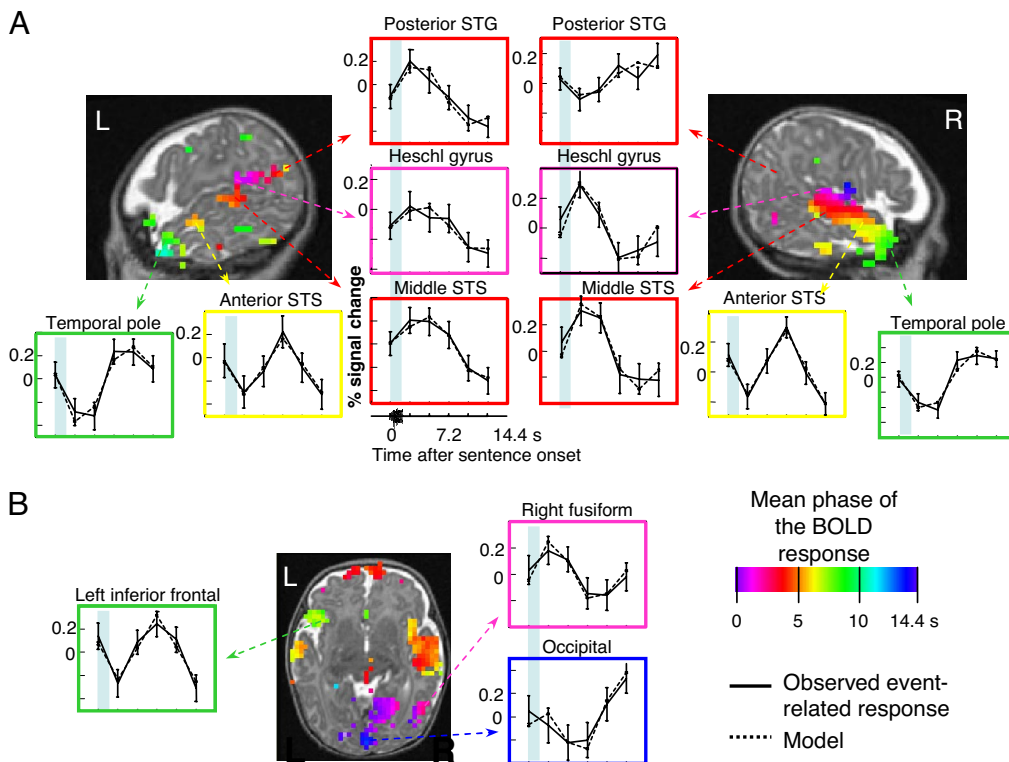


Fig. 1. Temporal organization of cortical responses to spoken language in infants. Data are modeled by a sinusoidal function with additional regressors accounting for head motion. Colors encode the circular mean of the phase of the BOLD response, expressed in s relative to sentence onset. We only show voxels with a significant oscillation in response to the periodical stimulation by short sentences (14.4 s; $P < 0.01$, Rayleigh test). Graphs show the mean BOLD response at different levels along the left and right superior temporal sulcus (STS) (A), where a phase progression away from Heschl's gyrus was observed, and in an axial slice through ventral occipito-temporal and inferior frontal cortex (B), where activation of the left-hemispheric Broca's area and deactivation in occipital areas are clearly visible. STG, superior temporal gyrus.

sured the phase at this frequency in each fMRI run and used the Rayleigh circular statistic to determine which voxels had a significantly reproducible oscillatory response (this test contrasts the observed distribution of phases to the null hypothesis of a uniform distribution across the phase circle; see *Materials and Methods*). At $P < 0.001$, significant BOLD oscillations in response to the periodical stimulation were observed mainly along the right superior temporal sulcus, from a region anterior to Heschl's gyrus all of the way to the temporal pole. At a lower threshold of $P < 0.01$ (Fig. 1), the significant regions were bilateral along the superior temporal regions, from a region now posterior to Heschl's gyrus all of the way to the temporal pole. The superior temporal activations extended more posteriorly and dorsally in the left hemisphere than in the right, at a location corresponding roughly to Wernicke's area. Active clusters were also found in the right and left insula and left inferior frontal gyrus. Finally, we observed clusters in the superior frontal cortices, mesial occipital areas, right fusiform gyrus, cerebellum, posterior part of the brainstem (colliculi), and basal ganglia.

Latency Shifts Across Brain Regions. Although all of the above regions showed an oscillatory stimulus-related signal change, they were distinguished by systematic differences in their phase. As shown in Fig. 1, the mean phase showed a systematic progression across the temporal lobe bilaterally, extending into the left frontal region. The phase of the BOLD response was fastest (phase ≈ 3 s) in the superior temporal gyrus surrounding Heschl's region (pink regions in Fig. 1). The phase then became progressively slower as one moved away from Heschl's region posteriorly toward Wernicke's area on the left side and anteri-

only on both sides along the superior temporal sulci (≈ 5 s, red regions in Fig. 1). Responses were slowest in the temporal poles and left inferior frontal gyrus (≈ 7 – 9 s, yellow and green regions in Fig. 1).

We also observed mean phases between 10 and 14 s in several bilateral regions, including the mesial occipital cortices, superior frontal cortices, and caudate nuclei (turquoise and blue regions in Figs. 1 and 2). These counterphase regions may correspond to deactivations in response to sentences, as have been reported in adults during a variety of cognitive tasks (7). For direct comparison, Fig. 2 shows selected slices from a similar study in 10 adult subjects, with the same sentences and the same period of 14.4 s (6). Several basic features are present in both adults and infants: progression of phases along the temporal lobe, slowest response in the left inferior frontal region, and counterphase responses in a distributed network associated with the resting state in adults.

Although the different slices in an fMRI volume were not acquired simultaneously, several arguments make it unlikely that slice acquisition delays contributed much to the observed temporal gradient. First, the delays in infants were qualitatively similar to those seen in adults, in whom a correction for slice acquisition times was implemented (6) (this correction could not be performed in the infant data because the time series became discontinuous after rejection of severely artifacted images; see *Materials and Methods*). Second, acquisition was from bottom to top, whereas BOLD responses were, in most cases, slower at the base of the brain (Fig. 1). Third, the range of observed phase lags (3–9 s) exceeded that of the slice acquisition lags (2.4 s at most). Fourth, areas with different delays could be observed within the same slice (Figs. 1 and 2).

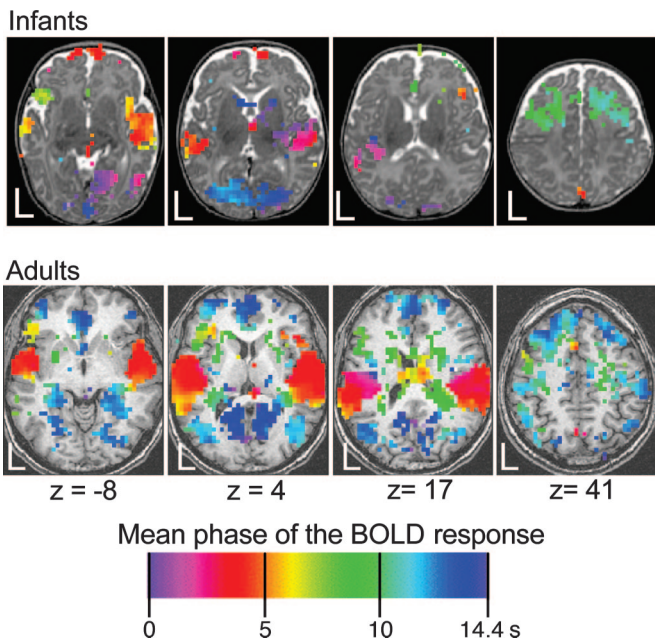


Fig. 2. Comparison of cerebral responses to a single sentence in infants and adults. The mean phase is presented on axial slices placed at similar locations in the infant (*Upper*) and adult (*Lower*) standard brains. The same temporal gradient is observed in adults and infants. The larger lags (coded in shades of blue) correspond to regions responding in counterphase with the stimulation and which may correspond to a “resting state” network.

Random Effect Analyses. To further investigate the significance of activations relative to rest and to search for sentence repetition effects, we performed a random-effect analysis in 10 infants. In an effort to capture the observed phase delays, the regression model used included both fast and slow regressors for each sentence, corresponding respectively to sentence onset and mean sentence offset, each convolved by a standard hemodynamic function. Relative to the intertrial rest period, sentences induced bilateral activations in the superior temporal sulci and gyri, extending more posteriorly on the left side than on the right (Fig. 3 and Table 1). The left inferior frontal region (Broca’s area) was the only region showing significantly greater activation to the slow than to the fast regressor. This was also the only region sensitive to sentence repetition. In this region, a significant interaction between presentation (second-first) and response (slow-fast) was observed because of a larger response by repeated than by novel sentences around the time of sentence offset (repetition enhancement; Fig. 3).

Discussion

Our results indicate that 2-s-long sentences are sufficient to activate a network of perisylvian areas. The use of a slow event-related design coupled with sentence repetition allowed us to reveal two characteristics of this network: a sequential organization of activations along the superior temporal and inferior frontal regions and a repetition enhancement effect in the left inferior frontal region. We now discuss how these results relate to the linguistic capacities observed at this age and how they might constraint language learning theories. Although our results reveal a functional organization of speech-responsive regions in infants, we would like to stress that, pending the use of nonspeech stimuli, we remain neutral on the issue of whether some of these regions are specific for language processing. This issue remains an important topic for further inquiry.

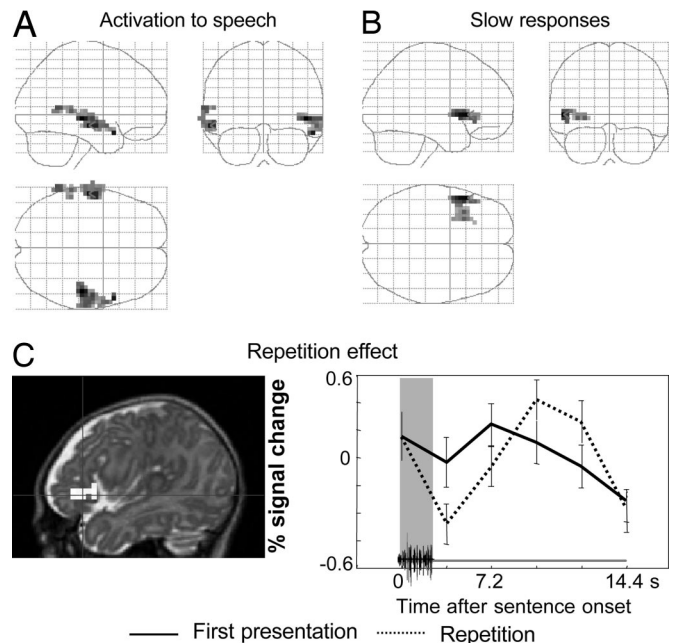


Fig. 3. Random-effect analyses of infant brain activation modeled with a standard adult hemodynamic response function. (A) Regions activated by speech are shown. (B) Regions displaying significantly slower responses are shown. (C) Shown is the increase in activation in Broca’s area in response to the repetition of the same sentence after a 14-s interval, at the peak (cross on the sagittal slice) of the significant cluster observed in the random-analysis comparing the interaction between slow-fast response and the first and second presentation of the sentences.

Sequential Organization of Activations. Our use of a slow event-related design allowed us to demonstrate a temporal structure along the perisylvian regions. Fast responses were observed in Heschl’s gyrus, whereas anterior temporal and inferior frontal regions showed much slower responses, the temporal pattern of the BOLD response in the anterior regions being better modeled by sentence offset than by sentence onset. Although variability in the hemodynamic response across immature brain areas may contribute to the observed phase lags, it is unlikely to suffice to explain the observed difference because a similar temporal gradient was observed in the mature cortex of adults (6, 8) (Fig. 2). Furthermore, in adults the time lag between different regions is not fixed, as would be expected if it was solely imputable to hemodynamics, but can be shortened or stretched when experimental conditions are modified (6, 9–12), suggesting that time lags can inform about neuro-cognitive processes.

Here, the observed sequential activation fits with the known organization of auditory connections. In humans, as in other primates, auditory processing progresses from core, to belt, to parabelt, to surrounding areas in the superior temporal sulcus, and to more distal polysensory areas through distinct ventral and dorsal pathway (13, 14). Axonal and synaptic transmission delays, which do not exceed a few tens of milliseconds, are unlikely to be the sole explanation of the large observed fMRI phase lags. Rather, this temporal gradient of activation might be the result of different cognitive operations that integrate over increasingly larger and possibly more abstract speech units and may therefore require longer processing time or more sustained activity. Although Heschl’s gyrus, and its surroundings appear “in line” with the auditory stimulus, increasingly anterior regions and Broca’s area would be involved in an analysis of larger chunks of the speech stream that would require longer processing time, possibly even having to wait until sentence completion. Indeed, it is known that young infants are already sensitive to

Table 1. Results of random-effect analyses of 10 infants (Wilcoxon *w* test)

Analysis	Area	Infant template coordinates			Permutation <i>w</i> tests		
		x	y	z	No. of voxels in cluster	Cluster-level <i>P</i> value (corrected)	Z value at local maximum
Activation to speech	Left STS	-40	-9	-9	99	0.009	3.1
	Wernicke's area	-49	-37	6			
	Right STS	37	-17	-3			
2nd sentence presentation	Left IFG	-37	11	9	80	0.022	3.1
	Left STS	-46	-37	3			
	Wernicke's area	-49	-14	-9			
Slow response	Left IFG	-34	14	-3	95	0.012	3.1
Slow > fast responses	Left IFG	-37	11	0	74	0.033	3.1
	Left insula	-23	9	0			
Interaction response × sentence presentation	Left IFG	-31	17	-3	78	0.019	3.1
	Left insula	-26	6	0			
Slow > fast responses restricted to the 2nd sentence presentation	Left IFG	-34	17	-3	85	0.016	3.1
2nd > 1st presentation restricted to slow responses	Left IFG	-31	17	-3	100	0.007	3.1
	Left insula	-20	17	-6			
1st > 2nd presentation restricted to fast responses	Left IFG	-29	17	-3	51	0.055	3.1
	Left insula	-20	14	-3			

Coordinates of the clusters maximum and their subpeaks are given relative to our infant brain template. They can be roughly compared to adult Montreal Neurological Institute coordinates after multiplication by a factor of 1.4. The voxel-wise significance level was set at $P < 0.01$. STS, superior temporal sulcus; IFG, inferior frontal gyrus.

different levels of sentence organization. Behavioral experiments have demonstrated a capacity to recognize the intonative contours of their native language (15), assess the number of syllables in words (16), and detect a change of phoneme (17) or a change of word order (18) in a sentence. In adults, a gradient of complexity as ones moves away rostrally and laterally from the primary auditory cortex is described (6, 19). The similarity of the temporal organization of responses across ages suggests that such a hierarchical processing scheme may already be present in 3-month-old infants and play a role in their perceptual abilities.

A Slow Response in Broca's Area, Sensitive to Sentence Repetition. In adults, activations in the left inferior frontal gyrus have been classically related to overt production of speech, inner speech, and short-term verbal memory. Parts of this region, which probably encompasses multiple functionally distinct regions, are also active during syntactic judgements (20) and metaphonological tasks (21). The complexity of these functions, the protracted delay for speech production in infants, their immaturity in motor control, and the late maturation of frontal areas make the observation of activity in Broca's area rather unexpected at this age. At 3 months, infants are still far from being able to reproduce the sentences that we present them. At this age, their vocal productions are limited to short vocalizations consisting of vowels associated with yells, screams, and whispers. Canonical babbling, consisting of repetitive string of consonant/vowel syllables such as "bababa," and denoting a more refined and voluntary control of the articulators, usually begins ≈ 7 months, and cross-linguistic differences in babbling are not observed before 8 months of age (22). Yet, behavioral experiments have shown some early verbal memory capacities. Two-month-old infants are able to detect a small phonetic change between "the rat chased white mice" presented during a habituation phase and "the cat chased white mice" presented in the test phase, even though those phases were separated by a 2-min delay (23). They

are also able to detect a change of word order between two sentences in the same experimental paradigm (18). In these experiments a single sentence was repeated for several minutes. Here, we show that infants, using Broca's area, are able to memorize all or part of a single sentence presentation in sufficient detail as to detect its repetition 14 s later and to discriminate it from another utterance within the same language and the same voice.

Thus, the second presentation of the sentence produced a stronger response than the first (repetition enhancement) in infants, whereas in adults we observed a repetition suppression effect in broad temporal and inferior frontal regions (6). This difference may reflect the different linguistic and memory capacities at both ages. Although brain activity usually decreases with repetition in many areas, repetition enhancement has been replicably observed in adults when the repeated stimulus is initially unfamiliar (24), unattended (25), or degraded (26). Such enhancement is thought to reflect a learning-induced enlargement of the neural representation of the stimulus. By analogy, repetition enhancement in infants may indicate that a sentence learning mechanism is already at work. Regardless of its ultimate interpretation, this result constitutes some of the best evidence to date that a memory system based on Broca's area is already available to very young infants.

Broca's Area and the Relations Between Speech Perception and Production. The recent discovery of mirror neurons in the macaque ventral premotor cortex (27, 28), a region possibly homologous to Broca's area, has raised the hypothesis of a broader function of this region in action understanding and imitation (29), speech being considered in this context as a specialized and complex form of motor action. Indeed, our result may point to an early common frame relating speech perception and production, possibly providing an early and covert training to the (future) speech production apparatus. Behavioral evidence

shows that infants of that age already form cross-modal associations: They imitate facial movements that can be used for speech production, such as tongue protrusion, lip pursing, or mouth opening (30, 31), suggesting an early visuomotor loop. They are also able, to a certain extent, to link heard syllables with articulatory motor movements. For example, 2-month-old infants orient to the appropriate speaking face when they hear the vowels /a/ or /i/ (32). When exposed to auditory-visual movies of a woman producing vowels (/a/, /i/, or /o/), 3- to 5-month-olds produce vocalizations that approximate the target vowel (32).

Using diffusion tensor imaging, we have been able to visualize in the infant brain the two main fasciculi, the arcuate and the uncinate, that connect frontal and temporal areas (33). We tentatively propose that these connections provide the infant brain with an auditory motor loop by which the speech production system is informed, early on, of the identity and rhythm of speech inputs. Converging evidence is provided by a recent paper using magnetoencephalography, which reports the late (800 ms) coupling of a source in inferior frontal region with one in the superior temporal region when 6- and 12-month-olds, but not neonates, discriminate syllables (34).

Neuronal recordings from the monkey ventrolateral prefrontal region (areas 12 and 45) have identified neurons that respond to complex sounds, such as animal and human vocalizations, close to neurons responding to visual cues (35). Thus the ventrolateral prefrontal region may be ideally suited to compute the convergence of visual, auditory, and action codes. This potentiality might be exploited for speech perception and production in humans. Thus, Broca's area might serve in infants as an integrative node common to perception and production, starting to shape speech programs months before the infant's linguistic productions become fully structured.

Resting-State Activity in Infants? A final finding is that the infant brain shows a distributed pattern of deactivation relative to rest (Figs. 1 and 2). Such deactivations, in adults, are generally interpreted as reflecting an organized "resting state" or "default-mode" network, which is spontaneously active during the awake state and is temporarily suspended during stimulus- or task-oriented behavior (7). The present results suggest the presence of such a network in 3-month-old infants. At this age, the deactivated network comprises mesial occipital and superior frontal cortices and the caudate nuclei. There was no evidence for the large bilateral temporo-parietal and ventro-mesial frontal deactivations, which were easily observed in adults. If replicated, this observation would suggest that infant resting activity is initially dominated by sensori-motor and subcortical activity. This hypothesis meshes well with metabolic measurements that indicate that blood flow and glucose consumption at rest first surge in subcortical and sensori-motor in the first few weeks and only show a similar increase in associative cortical areas \approx 6–9 months of age (36).

Conclusion

Relative to the extensive theoretical work that has attempted to characterize the possible paths toward language learnability, infant brain imaging has the unique potential to reveal which aspects of infant brain organization actually support language acquisition. Our results suggest that perisylvian areas are activated by speech early in life, with a well defined temporal structure and a capacity for memorizing sentences. The present study does not reveal which aspects of this organization, if any, are specific for speech, and which would be equally engaged by nonspeech environmental sounds or other communication devices such as gestures. We merely note that the infant's behavioral repertoire, in the language domain, includes categorical perception of phonemes (37), normalization of the speech input (38), recognition and long-term storing of intonation contours (4), and episodic verbal memory. Neurologically, there is

a channeling of language processing toward the left perisylvian areas, which may result from multiple biases including maturation differences and early auditory asymmetries (see ref. 39 for example). Future work should examine whether such data imply language-specific genetic and neural mechanisms or whether they can be accounted for by generic learning mechanisms that adapt to the most frequent auditory input encountered by the infant, namely speech.

Materials and Methods

Participants. Ten healthy, full-term infants (four girls, six boys) were tested between 11 and 17 weeks after birth (mean age 103 days). No sedation was used. All parents gave their written informed consent for the protocol. The study was approved by a local ethical committee for biomedical research. A pediatrician (G.D.-L.) stayed with the infant inside the magnet room to check his wakefulness and comfort throughout the study. On the basis of visual inspection, only one infant was judged asleep (no relevant differences were seen when his data were excluded). See *Supporting Text*, which is published as supporting information on the PNAS web site.

Stimuli. A female French speaker was recorded reading a children's story with a vivid theatrical intonation. A total of 36 sentences with a mean duration of 2,061 ms (1,823–2,380 ms) were extracted from the original story. Intonation, syntax, and lexical content were very different across sentences. These sentences were a subset of the sentences used in a published study of language discrimination (15).

Procedure. Scanning was performed on a 1.5-Tesla MR scanner (GE Medical System, Waubesa, WI). Precautions taken to protect infants, particularly from the noise of the machine, and to keep them quiet were as described (4).

Stimulation Procedure and Imaging Parameters. We used a slow event-related paradigm with a sentence presented every 14.4 s. To study short-term memory, each sentence was repeated once on the following trial. The different sentences were randomly ordered for each infant and delivered through piezoelectric loudspeakers inserted in noise protection earphones, with sides reversed for each successive infant. The level of sound presentation was adjusted to a comfortable level, easily understandable above the residual scanning noise by a normal adult. Each fMRI run comprised 12 stimuli corresponding to six different sentences repeated once.

MRI testing lasted <40 min and was stopped at any point if the infant showed discomfort. It began with an anatomical sequence followed by one to seven functional sequences (average 3.9 sequences per subject). T2-weighted spin-echo images were acquired for anatomical reference [32 contiguous axial slices of 3-mm thickness, 256×256 matrix, voxel size $0.938 \times 0.938 \times 3$ mm³, repetition time (TR) = 6,000 ms, echo time (TE) = 120 ms]. The selected slices covered 9.6 cm and systematically included the cerebellum and occipital regions. The same volume was then imaged with a gradient-echo echo planar image (EPI) sequence (16 axial slices of 5.5-mm thickness with a gap of 0.5 mm, 64×64 matrix, voxel size = $3.75 \times 3.75 \times 5.5$ mm³, TR = 2400 ms, TE = 60 ms). A total of 72 EPI volumes were acquired on each sequence. Four initial dummy scans, corresponding to an initial silent period of 9.6 s, were used to achieve steady-state magnetization.

Data Processing and Analysis. Data processing was performed by using a customized version of statistical parametric mapping software (SPM99). Each EPI volume was visually examined, and volumes with severe movement artifacts were rejected. On average 260 volumes were kept for analysis (range 65–483). For movement correction, all EPI volumes were realigned to an EPI

volume devoid of artifacts, using a six-parameter linear transform. EPI volumes were then coregistered with the subject's anatomical T2 image by using SPM's default coregistration algorithm. The quality of the coregistration was visually inspected and manually corrected if necessary. Data were then normalized to the infant template as described (4) by first computing a nonlinear normalization transformation on the infant's anatomical image, then applying the same transformation to each EPI volume. For localization, activations were superimposed on a $1 \times 1 \times 1\text{-mm}^3$ T2-weighted anatomical image acquired in an infant and registered to the infant template. EPI volumes were resampled by using a sinc function and $4 \times 4 \times \text{mm}^3$ voxels, then smoothed by using a 5-mm Gaussian kernel.

To accommodate the high level of motion in infant EPI data, the six movement parameters (three rotations, three translations) were entered as regressors of noninterest capable of capturing motion-induced changes in BOLD signal intensity. Second, SPM software was modified to allow voxels to stay in the analysis even if there was an occasional motion-induced signal loss (on at most 10% of volumes). Third, deviations of the signal of >2.5 SDs (measured within each voxel's time series) were clamped so that they did not exceedingly disrupt the fit of the general linear model. Fourth, the linear model of the BOLD response was adapted for temporal sequences with occasional missing data.

In a first analysis across the whole brain, we aimed to estimate the periodicity and phase of the event-related BOLD response in infants. For each subject and each session (total $n = 39$), the signal from each voxel was fitted with sine and cosine waveforms at the above period (together with six additional regressors for movement and a session-by-session constant offset). The regression weights of the sines and cosines were then transformed with the inverse tangent function to yield a phase lag expressed in s. The phase, originally between 0 and 2π , was converted in a fraction of the stimulation period of 14.4 s. A phase of 0 s thus indicates a peak activation synchronous with stimulus onset. Typical adult hemodynamic responses have a phase lag of 4–8 s. Statistical significance was assessed by a cohort analysis using the Rayleigh circular statistic, which contrasts the observed distribution of phases to the null hypothesis of a uniform distribution across the phase circle.

Second, we generated a general linear model for each subject with four variables corresponding to the onset and the mean offset of first and second sentence presentation, convolved by the standard adult hemodynamic response function. The individual contrast volumes obtained in each infant were smoothed with a 5-mm Gaussian kernel and submitted to one-sample statistics with subjects as the random variable. This analysis was limited to anatomically defined regions known to be involved in language processing in both adults and infants, i.e., the left perisylvian areas and their right-hemisphere homologs (inferior frontal lobe, insula, superior and middle temporal gyri and supramarginal gyrus: 3,052 voxels).

Because of the small number of subjects, we chose a nonparametric test known to be robust to outliers, i.e., the signed rank Wilcoxon test. Because cluster-level P values based on random field theory approximations have a limited validity domain (40), voxel-level and cluster-level significance levels were assessed by using sign permutations (41), meaning that the relevant null distributions were computed from the set of all possible pseudo data sets obtained by preserving or negating each individual contrast image (the number of possible permutations being $2^{11} = 2,048$ in this case). As discussed (41), the permutation procedure ensures exact specificity control under a mild symmetry assumption about the contrast distribution, hence relaxing the normality constraint. Furthermore, w tests are arguably more sensitive than t tests in the presence of heterogeneous observations, although less sensitive under the normal distribution. Classical SPM t tests are provided in Table 2, which is published as supporting information on the PNAS web site. We report activations significant at voxel level $P \leq 0.01$ and cluster level $P \leq 0.05$ after correction for multiple tests across the perisylvian volume.

We thank Thierry Brunet (Ravier-Touzard, Paris, France) for designing a baby chair specifically adapted to the head coil, Bernard Rieul for technical help, and Professors Francis Brunelle and Denis LeBihan for support. This study was supported by the McDonnell Foundation, Institut Fédératif de Recherche 49, Association pour l'Education Thérapeutique et la Réadaptation des Enfants Infirmes Moteurs Cérébraux, and a Human Frontiers Fellowship (to M.S.).

- Chomsky N (1986) *Knowledge of Language: Its Nature, Origin, and Use* (Praeger, New York).
- Saffran JR, Aslin RN, Newport EL (1996) *Science* 274:1926–1928.
- Elman JL, Bates E, Johnson M, Karmiloff-Smith A, Parisi D, Plunkett K (1996) *Rethinking Innateness: A Connectionist Perspective on Development* (MIT Press, Cambridge, MA).
- Dehaene-Lambertz G, Dehaene S, Hertz-Pannier L (2002) *Science* 298:2013–2015.
- Pena M, Maki A, Kovacic D, Dehaene-Lambertz G, Koizumi H, Bouquet F, Mehler J (2003) *Proc Natl Acad Sci USA* 100:11702–11705.
- Dehaene-Lambertz G, Dehaene S, Anton JL, Campagne A, Ciuciu P, Dehaene GP, Denghien I, Jobert A, LeBihan D, Sigman, M, et al. (2006) *Hum Brain Mapp* 27:360–371.
- Raichle ME, MacLeod AM, Snyder AZ, Powers WJ, Gusnard DA, Shulman GL (2001) *Proc Natl Acad Sci USA* 98:676–682.
- Kruggel F, von Cramon DY (1999) *Hum Brain Mapp* 8:259–271.
- Heim S, Friederici AD (2003) *NeuroReport* 14:2031–2033.
- Thierry G, Ibarrola D, Demonet JF, Cardebat D (2003) *Hum Brain Mapp* 19:37–46.
- Henson RN, Price CJ, Rugg MD, Turner R, Friston KJ (2002) *NeuroImage* 15:83–97.
- Sigman M, Jobert A, LeBihan D, Dehaene S (2006) *NeuroImage*, in press.
- Petrides M, Pandya DN (2002) *Eur J Neurosci* 16:291–310.
- Kaas JH, Hackett TA (2000) *Proc Natl Acad Sci USA* 97:11793–11799.
- Dehaene-Lambertz G, Houston D (1998) *Lang Speech* 41:21–43.
- Bijeljac-Babic R, Bertoni J, Mehler J (1993) *Dev Psychol* 29:711–721.
- Mandel DR, Jusczyk PW, Kemler-Nelson DG (1994) *Cognition* 53:155–180.
- Mandel DR, Kemler Nelson DG, Jusczyk PW (1996) *Cog Dev* 11:181–196.
- Davis MH, Johnsrude IS (2003) *J Neurosci* 23:3423–3431.
- Hashimoto R, Sakai KL (2002) *Neuron* 35:589–597.
- Burton MW, Small SL, Blumstein SE (2000) *J Cogn Neurosci* 12:679–690.
- Boysson-Bardies B, Sagart L, Durand C (1984) *J Child Lang* 11:1–15.
- Mandel DR, Jusczyk PW, Nelson DG (1994) *Cognition* 53:155–180.
- Henson R, Shallice T, Dolan R (2000) *Science* 287:1269–1272.
- Vuilleumier P, Schwartz S, Duhoux S, Dolan RJ, Driver J (2005) *J Cogn Neurosci* 17:1245–1260.
- Turk-Browne NB, Yi DJ, Leber AB, Chun MM (2006) *Cereb Cortex*, doi:10.1093/cercor/bhj159.
- Rizzolatti G, Fogassi L, Gallese V (2001) *Nat Rev Neurosci* 2:661–670.
- Kohler E, Keysers C, Umiltà MA, Fogassi L, Gallese V, Rizzolatti G (2002) *Science* 297:846–848.
- Heiser M, Iacoboni M, Maeda F, Marcus J, Mazziotta JC (2003) *Eur J Neurosci* 17:1123–1128.
- Meltzoff AN, Moore MK (1977) *Science* 198:74–78.
- Chen X, Striano T, Rakoczy H (2004) *Dev Sci* 7:42–47.
- Kuhl PK, Meltzoff AN (1982) *Science* 218:1138–1141.
- Dubois J, Hertz-Pannier L, Dehaene-Lambertz G, Cointepas Y, Le Bihan D (2006) *NeuroImage* 30:1121–1132.
- Imada T, Zhang Y, Cheour M, Taulu S, Ahonen A, Kuhl PK (2006) *NeuroReport* 17:957–962.
- Romanski LM, Goldman-Rakic PS (2002) *Nat Neurosci* 5:15–16.
- Chugani HT, Phelps ME, Mazziotta JC (1987) *Ann Neurol* 22:487–497.
- Eimas PD, Siqueland ER, Jusczyk PW, Vigorito J (1971) *Science* 171:303–306.
- Kuhl PK (1983) *Inf Behav Dev* 6:263–285.
- Sininger YS, Cone-Wesson B (2004) *Science* 305:1581.
- Worsley KJ, Marrett S, Neelin P, Vandal AC, Friston KJ, Evans AC (1996) *Hum Brain Mapp* 4:58–73.
- Holmes A, Blair R, Watson J, Ford I (1996) *J Cereb Blood Flow Metab* 16:7–22.